

Case Study of the Anatomic Changes Effected by a Mandibular Advancement Device in a Sleep Apnea Patient

A. J. Moses, J. A. Bedoya and J. A. Learreta

An imaging study is presented to advance understanding of how a Mandibular Advancement Device (MAD) used as therapy for Obstructive Sleep Apnea (OSA) changes the shape and volume of the oral airway.

Introduction

In lower animals the uvula overlaps the epiglottis. This anatomic arrangement separates the oropharynx from the nasopharynx and allows the animal to swallow and breathe at the same time. Human babies have this same anatomic configuration. At about six to nine months of age the epiglottis begins to descend and the uvula ascends such that by two years of age there is a vertical gap between them. Subsequent to age two in humans, the foodway and the airway share the same passage from the uvula to the epiglottis, and the boundaries of this area are all soft tissues. This creates a compliant, collapsible oropharynx. The front wall is the tongue and the side and rear boundary is the pharyngeal wall.¹

Humans are the only animals to have a collapsible oropharynx and the only animals with the ability to articulate speech. All vowel sounds are formed in this compliant, collapsible area. Speech is the advantage. The disadvantages in humans are the possibility of obstructive sleep apnea and choking.

The MAD actively repositions and supports the mandible in a more anterior and open position than the position of maximum interarch occlusion of teeth or physiological rest position of the mandible. The tongue is attached to the mandible on the lingual side of the symphysis, below the apex of the roots of the mandibular central incisors. As the mandible is actively advanced by the MAD, the tongue at its attachment is passively pulled anteriorly away from the back wall of the oropharynx.

MADs are approved by the American Academy of Sleep Medicine for use as primary therapy in cases of mild to moderate OSA and in patients with more severe OSA who cannot tolerate Continuous Positive Air Pressure (CPAP) therapy.³

What remains problematic is how MADs work. Studies report that MADs increase posterior airway space,^{4,5} and at least one that demonstrates no change in posterior airway space.⁶ Passive tongue advancement during general anesthesia has been reported to increase both retropalatal and retroglottal areas.⁷ Studies of the effect of protrusion consistently report that increased protrusion produces greater reductions in restricted respiratory

¹Assistant Professor, Rush University College of Medicine, Chicago IL, USA Department of Sleep Disorders.

²Universidad Diego Portales, Santiago, Chile Department of Oral Surgery.

³Universidad Catolica de Salta, Buenos Aires, Argentina Department of Orthodontics and Temporomandibular Pathologies.

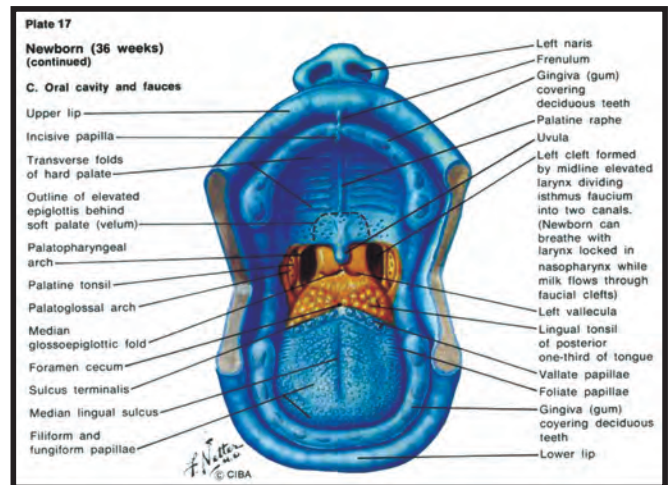


Fig. 1. Anatomic rendering of a 36 week old child showing the overlap of uvula and epiglottis.²

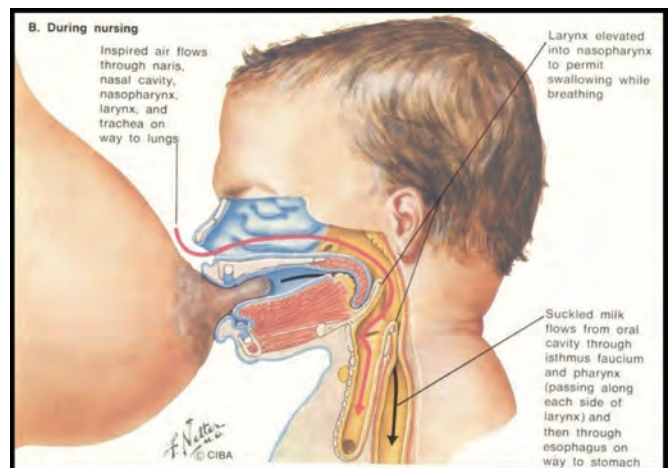


Fig. 2. Anatomic rendering of sagittal section of 36 week old infant showing uvula-epiglottis overlap shunting milk to the sides of the pharynx and the patent nasal airway. This arrangement allows an infant to swallow and breathe at the same time.²

events.^{8,9,10,11} Studies differ however on the impact of vertical opening related to device efficiency and the amount of jaw discomfort reported using the MAD.^{12,13,14,15}

The hydrostat theory of tongue function was proposed by Keir and Smith in 1985.¹⁶ It has been supported by scientific testing for almost a quarter of a century.^{17,18,19} The most important biomechanical characteristic of a muscular hydrostat

is that it is a structure of constant volume. Muscle tissue is composed primarily of an aqueous liquid which is practically incompressible at physiological pressures. Contraction of muscle does not change its volume. Any decrease in one dimension will cause a compensatory increase in at least one other dimension in a muscular hydrostat.

The tongue being a hydrostat, in reasoning the mechanism of action of a MAD, one must assume that tongue volume is a constant. A tongue might change its shape but the volume remains the same. MADs move the tongue out of the airway at night but to accommodate this change it must increase the volume of space for the tongue in the oral cavity.

Method

An open gantry cone beam 3 D computerized tomography scanner, the ICAT™ by Imaging sciences International was used

for this study. High resolution, 360° scans produced images at .2mm voxel size. 14 bit grayscale quality along all x, y, and z-axes produced clear images in cross-sectional views. A scan time of 40 seconds was used with beam collimation at full height. The x-ray source was a high frequency, constant potential, pulse mode at 120kVp and 3-8mA. The focal width is .5mm and the image detector is an amorphous silicon flat panel of 20cm. x 25cm.

The MAD used for this study was the Moses Appliance, a two piece open-anterior device. The upper element is a .3mm polypropylene-ethylene copolymer vacuum-formed splint covering all maxillary teeth and trimmed to not touch the gingiva. The lower element is made of methyl-methylacrylate and built to maintain the dental arches in a position at the maximum vertical height at which the patient can comfortably close the lips, and the maximum protrusive position that the patient can comfortably tolerate.

Results

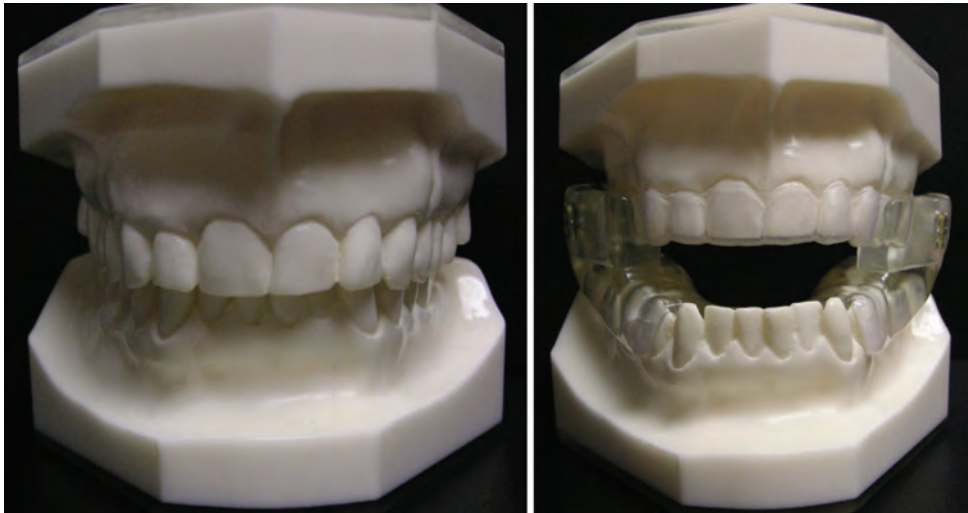


Fig. 3. The left photo above shows a frontal view of the patient's study models in centric occlusion. The right photo above shows the MAD positioned on the study models.

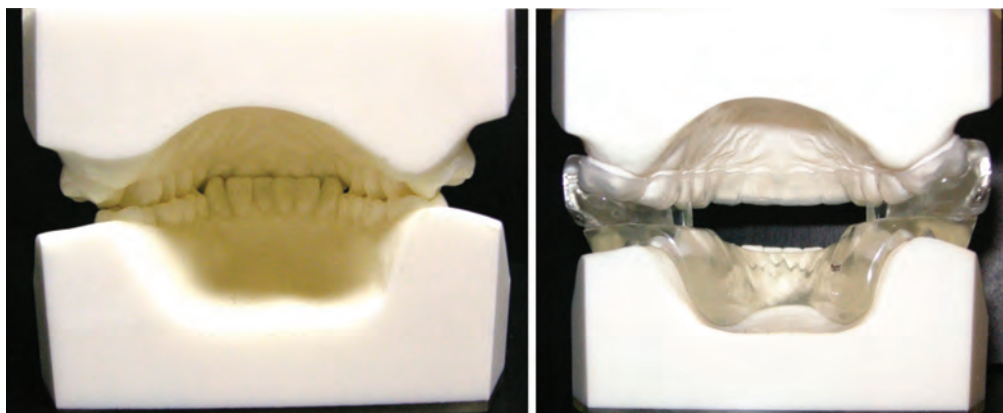


Fig. 4. The left photo above shows a rear view of the study models in centric occlusion. The right photo above shows a rear view of the MAD positioned on the study models. Note the dramatic increase in volume of space for the tongue in the right photo.

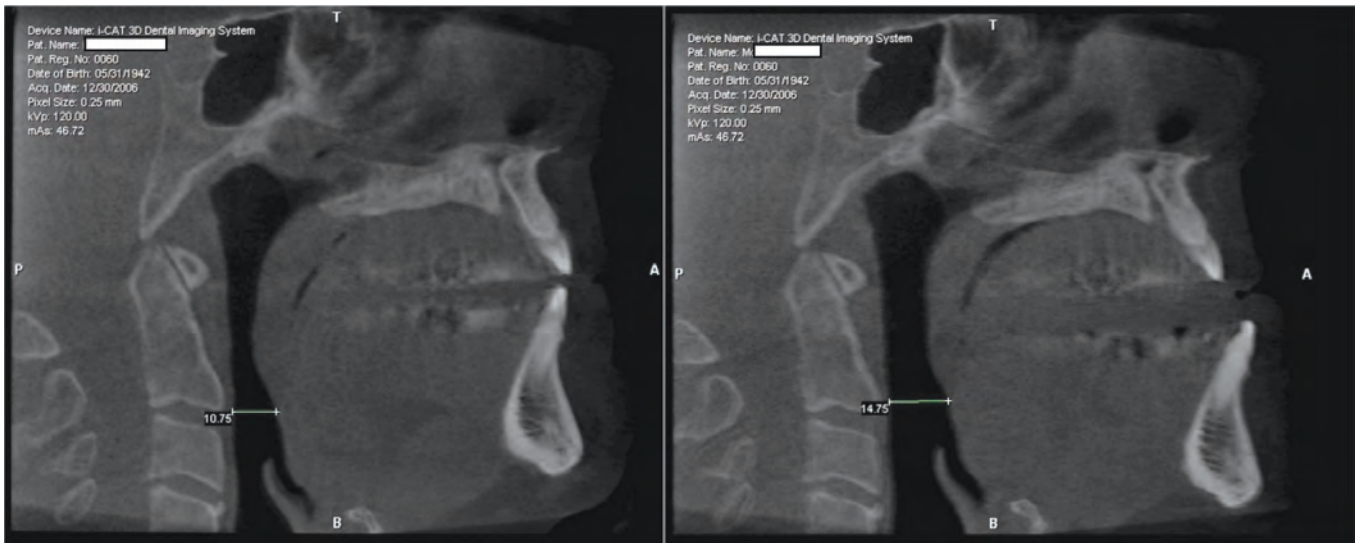


Fig. 5. The left CT image is a midline sagittal view of the head without MAD. The patient is instructed to keep lips together, teeth slightly apart in a resting position and tongue in the roof of the mouth. This is a typical posture for a nose breather. The marker measuring sagittal airway space (10.75 mm) was taken at the base of the second cervical vertebrae for accuracy and consistency of scientific measurement. It is obvious that the airway is narrower above the marker but not based on a reproducible fixed landmark. The right CT image is taken with the MAD in proper position in the mouth. The patient is instructed to keep lips together, teeth where they fit into the appliance and tongue in the roof of the mouth. This image clearly shows a dramatic increase in the sagittal airway dimension (14.75 mm), approximating 40%.

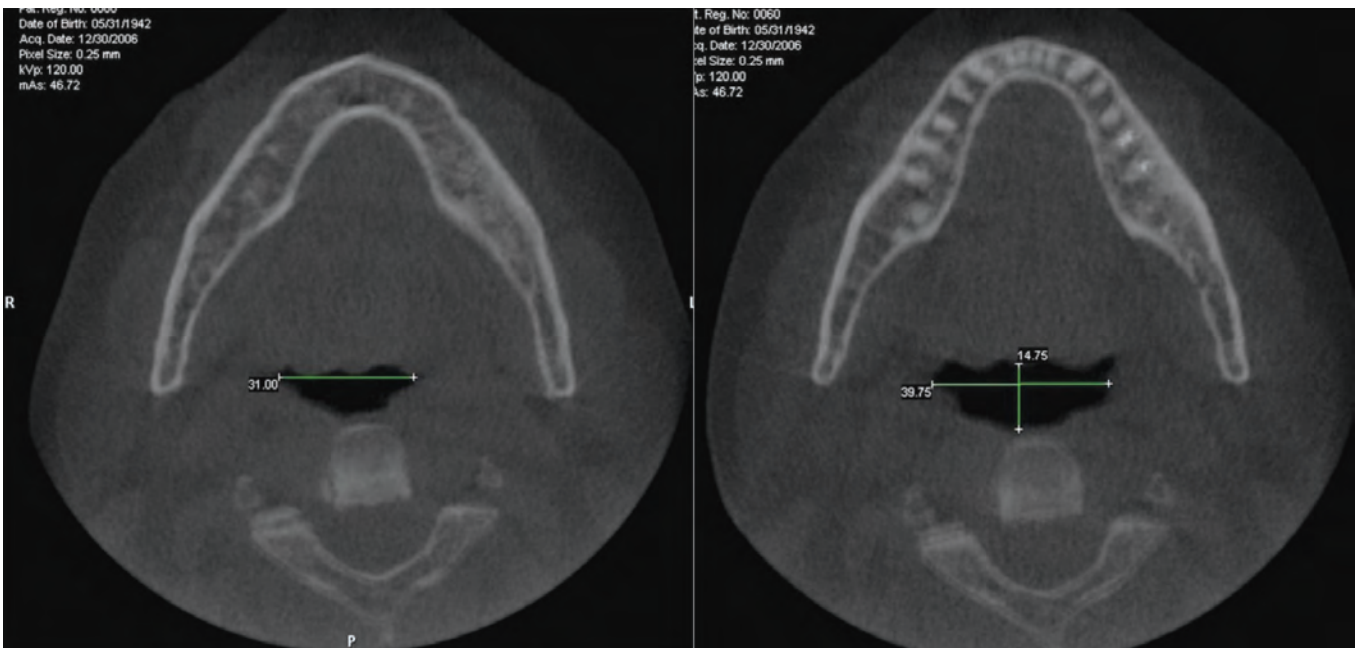


Fig. 6. Both CT sectional views above are at the same level at the base of the second cervical vertebrae as those shown in Figure 5. The left image of the patient without appliance has the same anteroposterior measurement of 10.75 mm (not marked) and a lateral measurement of 31.00 mm. The image on the right above (again at the same level as Figure 5 – 14.75 mm) shows a lateral measurement of the airway of 39.75 mm. Noteworthy is that the apparent sagittal effect of the MAD is accompanied by a lateral expansion of the airway approximating 25% at this level.

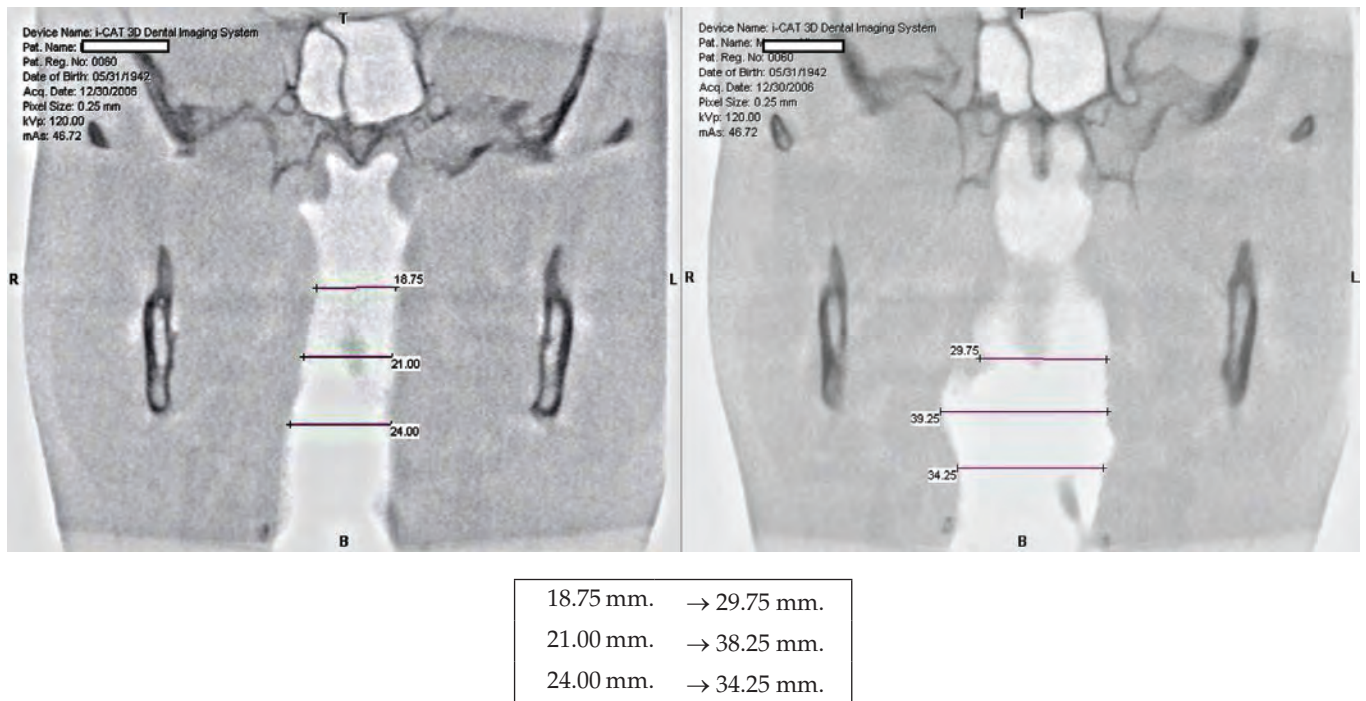


Fig. 7. Frontal CT scans measure the lateral dimensions of the airway without appliance (left) and with appliance in place in mouth (right). The wider airway on the right with the appliance in place is obvious. The markers appear to be at different levels on the right and on the left but that is because with the appliance in place the position of the mandible, head and airway has moved relative to the vertebrae. The three measurements shown in each scan are at the same level in the airway.

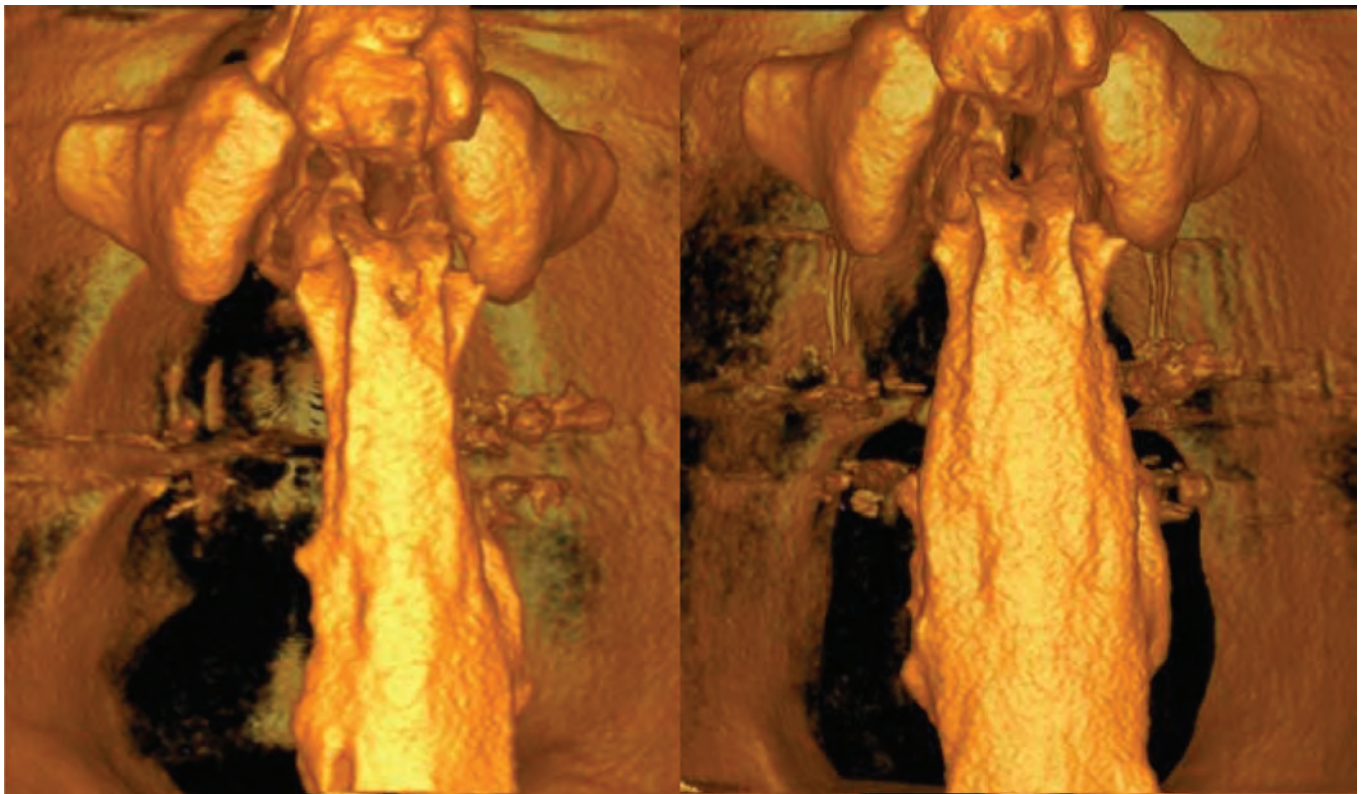


Fig. 8. Left image above is a posterior view of a three dimensional volumetric reconstruction of the patient's airway without MAD. Right image is a posterior view of a three dimensional reconstruction of the patient's airway with MAD properly positioned in the mouth. The increase in size of the airway is substantial and obvious.

Discussion

The effectiveness of MADs used as treatment for OSA have been thoroughly referenced in an updated (2006) American Academy of Sleep Medicine review paper.²⁰ That MADs work is well established. How they work is a subject of continuing research.

This case report demonstrates that the MAD studied, constructed to a jaw position of increased vertical and sagittal position substantially increases the size of the airway lumen in the retroglossal and palatal regions in all possible dimensions. The term oral airway dilator may be a more suitable descriptor than simply mandibular advancement device.

This study was done with the patient awake and seated upright. A preliminary study by the lead author using a different CT scanner with the patient in the supine position did not show any appreciable changes in awake airway measurements. Sleep could certainly affect the airway dynamics from upright and awake to the sleep state. The actual role of the tongue during sleep was not directly dealt with in this study. It is certainly an excellent subject for a future research study.

References

1. Crelin ES, *The human Vocal Tract: Anatomy, Function, Development and Evolution*, Vantage Press, New York, 1987.
2. Netter F, illustration in Crelin ES, *Development of the Upper Respiratory System, Clinical Symposia*, Vol 28, Num. 3, 1976, Ciba Pharmaceutical Co, New Jersey.
3. Kushida CA, Morgenthaler TI, et.al. Practice Parameters for the Treatment of Snoring and Obstructive Sleep Apnea with Oral Appliances: An Update for 2005. *Sleep*, Vol 29, No 2, 2006, p 240–243.
4. Ishida M, Inoue Y, Suto Y, et.al. Mechanism of Action and Therapeutic Indication of Prosthetic Mandibular Advancement in Obstructive Sleep Apnea Syndrome. *Psychiatry Clin Neurosci*, Vol 52, 227–229, 1998.
5. Schmidt-Nowara WW, Meade TE, Hayes MB, Treatment of Snoring and Obstructive Sleep Apnea with a Dental Orthosis, *Chest*, Vol 99, p 1378–1385.
6. Eveloff SE, Rosenberg CL, Carlisle CC, Millman RP, Efficacy of a Herbst Mandibular Advancement Device in Obstructive Sleep Apnea, *Amer J Respir Crit Care Med*, Vol 149, P 905–909, 1994.
7. Isono S, Tanaka A, Sho Y, et.al. Advancement of the Mandible Improves Velopharyngeal Airway Patency, *J Appl Physiol* Vol 79, 2132–2138, 1995.
8. Walker-Engstrom ML, Ringqvist I, Vestling O, et.al. A Prospective Randomized Study Comparing Two Different degrees of Mandibular Advancement With a Dental Appliance in Treatment of Severe Obstructive Sleep Apnea, *Sleep Breath* Vol 7, P 119–130, 2003.
9. Esaki K, Kanegae H, Uchida T, et.al. Treatment of Sleep Apnea with a New Separated Type of Dental Appliance (Mandibular Advancing Positioner). *Kurume Med J*, V44, p315–319, 1997
10. Marklin M, Franklin KA, Sahlin C, et.al. The Effect of a Mandibular Advancement Device on Apneas and Sleep in Patients with Obstructive Sleep Apnea, *Chest*, Vol 113, p 707–713, 1998.
11. De Almeida FR, Bittencourt LR, de Almeida CI, et.al. Effects of Mandibular Posture on Obstructive Sleep Apnea Severity and the Temporomandibular Joint in Patients fitted with an Oral Appliance, *Sleep*, Vol 25, p507–513, 2002.
12. Pitsis AJ, Darendaliler MA, Gotsopoulos H, et.al. Effect of Vertical Dimension on Efficacy of Oral Appliance Therapy in Obstructive Sleep Apnea, *Am J Resp Crit Care Med*, Vol 166, p 860-864, 2002.
13. Rose E, Staats R, Virchow C, et.al. A Comparative Study of Two Mandibular Advancement Appliances for the Treatment of Obstructive Sleep Apnea, *Eur J Orthod* Vol 24, p191–198, 2002.
14. Pantin CC, Hillman DR, and Tennant M, Dental Side Effects of an Oral Device to Treat Snoring and Obstructive Sleep Apnea, *Sleep*, Vol 22, p237–240, 1999.
15. Bondemark L, Does 2 Years' Nocturnal Treatment with a Mandibular Advancement Splint in Adult Patients with Snoring and OSAs Cause a Change in the Posture of the Mandible? *Am J Orthod Dentofacial Orthop* Vol 116, p 621–628.
16. Keir WM, Smith KK, Tongues, Tentacles, and Trunks: the Biomechanics of Movement in Muscular Hydrostats, *Zoo J Linnaea Soc*. Vol 83, p307–324, 1985.
17. Bailey EF, Fregosi RF, Coordination of Intrinsic and Extrinsic Tongue Muscles During Spontaneous Breathing in the Rat, *J Appl Physiol*, Vol 96, p.440–448, 2004.
18. Gilbert RJ, Napadow VJ, Gaige TA et.al. Anatomic Basis of Lingual Deformation, *J Exp Biol*, Vol 210, No 23, 2007.
19. Levine WS, Torcaso CE, Stone M, Controlling the Shape of a Muscular Hydrostat: A Tongue or a Tentacle? Springer Berlin, Heidelberg, Vol 321, 2005.
20. Ferguson KA, Cartwright R, Rogers R, et. al. Oral Appliances for Snoring and Obstructive Sleep Apnea: A Review, *Sleep*, Vol 29, No 2, p 244–262, 2006.